

## Evaluation of Aesthetic Contour of the Abdomen: In Different Post-Bariatric Abdominoplasties

RASHA ABDELKADER, M.D.; AHMED NAWAR, M.D.; AHMED ABDELSALAM, M.D. and  
ASHRAF EL-SEBAIE, M.D.

*The Department of Plastic & Reconstructive Surgery, Faculty of Medicine, Cairo University*

### ABSTRACT

**Background:** Given the sizeable increase in the number of recent post bariatric weight loss patients due to advances in that field, there has been an emphasis in treatment of lower truncal deformities and their evaluation; abdominoplasties being at the core of body contouring procedures. The aim of this study was to evaluate the benefits and risks for patients having different approaches for abdominoplasty after bariatric surgery and to try and classify post bariatric surgery patients, seeking abdominoplasty and accordingly the most suitable procedure is done for every individual patient. Analysis of the final results to compare different procedures and evaluate them individually and comparatively in an effort to categorize the overall benefit of each procedure.

**Patients and Methods:** A total of 30 female patients were included in this study who had all underwent successful bariatric surgery. The body mass index (BMI) in all patients was below 30. All patients were subjected to pre as well as post-operative fixed measurements: Xiphoid to umbilicus (XU), umbilicus to symphysis pubis (US), the total vertical height (XS) and waist circumference. Patients were classified into three groups according to the distribution of skin laxity in the abdomen (both vertical and horizontal components where considered), buttocks and flanks.

**Results:** Each of the three test groups showed a significant improvement in waist circumference difference, as well as a significant difference between the pre and post operative vertical length. The overall comparison between the 3 groups also proved to be significantly different as regards the waist circumference difference ( $p$ -value  $<0.005$ ).

**Conclusion:** The proper choice of the technique of abdominoplasty for post bariatric patient depends on the distribution of excess laxity, whether classical abdominoplasty is done or whether circumferential laxity where circumferential abdominoplasty is done or ventral laxity where classic or Fleur-de-lis abdominoplasty is done. This was also evident in the patient satisfaction results and overall surgeon evaluation. In General, post-bariatric procedures have a strong impact on the quality of life of the patients undergoing the procedures, most significantly affecting their "self-image" and their "self-esteem".

**Key Words:** *Abdominoplasty – Lipectomy – Post bariatric abdominoplasty – Aesthetic abdominal evaluation – Circumferential abdominoplasty – Fleur-de-lis procedure – Classical abdominoplasty.*

### INTRODUCTION

Abdominoplasty has undergone a significant increase in popularity over the last ten years. Hence, Abdominoplasty techniques have undergone a continuous process of evolution in an ongoing effort to reach better and safer results [1].

The post-bariatric surgery patients present surgeons with numerous challenges. These patients often suffer from residual medical co-morbidities, nutritional deficiencies, and other psychological issues in addition to their complex body habitus. The lower truncal region shows different deformities that entail different modalities for their treatment.

These problems make body-contouring procedures high risk. Also, correction of any skin and subcutaneous redundancy can prove to be difficult, particularly in post bariatric surgery patients with horizontal laxity, upper abdominal redundancy, flank laxity, or "double-roll" deformities [2].

Although some patients can be classified according to the abdominoplasty system of categorization of Bozola [3], in many cases such classification is not possible due to the excessive amount of loose skin and subcutaneous tissue that accompany the weight loss, that necessitate another classifying systems.

The classical (conventional abdominoplasty) procedures ranging from a full abdominoplasty down to lipoplasty commonly do not adequately treat the patient. In fact, many patients have skin and subcutaneous tissue excess of both the vertical and horizontal abdominal components, which contributes significantly to their overall girth.

The circumferential (belt) lipectomy as the ones illustrated by Glonzalez-Ulloa [4] and Muhlbauer

[5], are not ideal for treatment of the circumferential laxity contributing to the girth of the abdomen, mainly in the supra-umbilical region, however, have address adequately the over-hanging pannus.

Castanares and Goethel described Fleur-de-lis patterns, which consider and treat both the vertical and horizontal laxity; by addressing the circumferential component from the infra-umbilical region, in addition combining an inverted "V" pattern of excision from the supra umbilical region [6]. Incorporating the fleur-de-lis pattern for the abdomen with techniques described for the flank and buttock regions allows for the successful treatment of the circumferential component.

Given the sizeable increase in the number of current post bariatric weight loss patients due to advances in that field, there has been an emphasis in treatment of lower truncal deformities and their evaluation.

The aim of current study was to evaluate the benefits and risks for patients having different approaches for abdominoplasty after bariatric surgery and to try to classify post bariatric surgery patients seeking abdominoplasty, and accordingly the most suitable procedure is done for every individual patient.

## PATIENTS AND METHODS

A total of 30 female patients were included in this study who had all underwent successful bariatric surgery, had reached a stable weight for at least 1 year and suffered from a redundant torso.

The study was executed in the period from January 2013 to July 2016 in Kasr El Aini Hospital among other private hospitals.

The mean age of the patients was 35 years (range 17-45 years). The body mass index (BMI) in all patients was below 30. There were no active smokers and none of the patients suffered from peripheral vascular disease. 14 patients had single or multiple previous abdominal surgeries and 6 patients had scars in the upper abdomen. Also 7 of the cases presented with anterior wall hernias.

It is important to note that neither laparoscopic access ports nor vertical scars cause impairment to the abdominal flap in contrast to transverse scars that may require individualized approach.

All patients were subjected to pre as well as post-operative evaluation via fixed measurements: xiphoid to umbilicus (XU), umbilicus to symphysis

pubis (US), the total vertical height (XS) and waist circumference in each group the pre and postoperative measurements were compared.

Patients were classified in to three different groups according to the distribution of skin laxity in the abdomen (both vertical and horizontal components where considered), buttocks and flanks. Patients were then regarded according to the abdominal laxities those with horizontal abdominal laxity only underwent conventional abdominoplasty Patients with a horizontal abdominal laxity and a laxity of the buttock and flanks areas underwent a circumferential abdominoplasty. Those presenting with a vertical abdominal skin laxity underwent a fleur-de-lis abdominoplasty in addition patients further suffering from buttock and flank redundancy a circumferential fleur-de-lis was performed.

*The patients were then grouped into three equal categories:*

- *Group A:* Ten patients underwent conventional abdominoplasty with assistance of liposuction of back, supra-gluteal region, flanks and epigastrium as well.

At a minimal distance of 7cm from the anterior commissure of the vulva low in the inguinal folds a horizontal mark is done that is extended laterally according to the excess skin of the flanks. The upper border of the ellipse of resection is determined during the operation. As pitanguy [7], a conventional full abdominoplasty is performed via the low horizontal skin incision the flaps are elevated centrally to the xiphoid process and laterally to the costal margins. Following which the removal of the skin and subcutaneous excess is conducted. The lifting effect can include the whole area of the abdominal flap to the xiphoid. Circumcision and reinsertion of the umbilicus via an incision through the abdominal flap. Plication of the rectus muscle fascia is added in case of true diastasis from the xiphoid process to the symphysis pubis. The wound is then closed in layers after placement of suction drains.

- *Group B:* Ten patients underwent circumferential abdominoplasty with lifting of buttocks area and lateral thighs as well as the pubic area. In the circumferential abdominoplasty the skin resection pattern has to be meticulously drawn to avoid any unpleasant contour and/or asymmetry. It is also important to camouflage the incision along the underwear line type worn by each individual patient determining the upper border of the incision in the mid-axillary line. To determine the lower border a pinch test is done bilaterally. Posteriorly in the

midline the lower limit is just above the gluteal crease and pinching determines the upper limit.

In the prone position the skin and subcutaneous tissues on the back are first incised full thickness undermining is then done following the preoperative markings. Excess fat tissue resected followed by closure in layer. Patient is then turned over to the supine position for abdominal contouring following the same principle as in the conventional technique.

- *Group C:* The last ten patients underwent surgery using a fleur-de-lis pattern; 7 patients underwent a circumferential procedure and the other 3 patients underwent an isolated abdominoplasty. Fleur-de-Lis (T-type) abdominoplasty procedures are most suitable in cases presenting with both, vertical and horizontal laxities [8]. A T-type circumferential body lift can be performed in cases with additional buttock and flank laxity, dealing with the respective units. Markings of Fleur-de-Lis abdominoplasty consists of both a vertical and horizontal element, excess abdominal tissue is excised to reconstruct the abdominal wall along with mons pubis contour. After removal of a cloverleaf-like piece of tissue, the lateral tissue is then transposed medially, thereby leading to extended resection. Also, rectus divarication can be addressed if needed.

The follow-up period for patients in this study ranged from 4 months to 2 years, with an average follow-up of 9.5 months.

Patients were scheduled for weekly visits in the first month, then every 2 weeks in the second and once every month for 6 months, and the patients who were followed-up for less than 3 months were excluded from the study.

Statistical results were described in terms of mean  $\pm$  standard deviation ( $\pm$  SD), range, and 95% CI. Comparison between the study groups was performed using one-way analysis of variance (ANOVA) test with posthoc multiple 2-group comparisons. Within group comparison between before and after treatment was done using paired *t*-test. *p*-values less than 0.05 was considered statistically significant. Statistical calculations were performed using the SPSS software (Statistical Package for the Social Science) version (2006).

## RESULTS

In the 30 female patients in this study the mean age of the patients was 35 years (range, 17-45 years). The body mass index (BMI) in all patients

was below 30. There were no active smokers and none of the patients suffered from peripheral vascular disease. 14 patients had single or multiple previous abdominal surgeries and 6 patients had scars in the upper abdomen. Also 7 of the cases presented with ventral wall hernias.

All patients were subjected to preoperative evaluation via fixed measurements including the xiphoid to umbilicus (XS), the umbilicus to symphysis pubis (US) and the total waist circumference in each group the pre and postoperative measurements were compared.

Each of the three groups showed a significant improvement in both waist circumference and vertical length noted in as the difference between the pre and post operative xiphi-sternum to umbilical distance (*p*-value <0.05). However no significant difference was found in umbilical to the symphysis distance (*p*>0.05).

The overall comparison between the 3 groups also proved to be significantly different in waist circumference with mean value being -6.8 in group A, -11.40 in group B and -17.60 in group C (*p*-value <0.005); however all other measurements proved to be statistically insignificant.

In addition three plastic surgeons not involved in the surgical procedures gave scores without identification of the patients. The assessment was individual, and photographs were used. Preoperative standardized digital pictures of each patient were organized in one slide including frontal and profile, and in a separate slide, the same views of each patient in postoperative photographs were organized.

In each individual group the achievement of each of the following parameters was evaluated regarding the level of satisfaction with the procedure results, so that they received 0 points for unsatisfactory, 1 point for moderately satisfactory, and 2 points for extremely satisfactory. The parameters were Supra Umbilical Contour, Infra umbilical contour, Symmetry, Waist Definition, Excess Skin, Quality and length of scars, and Aspect & Position of the Navel.

Each individual criteria was scored from 0-2, with a check list to guide the scoring of each parameter. The sum of the scores for each parameter given by each examiner provided a final grade with a possible range of 0-14.

0-4 being poor, 5-9 good & 10-14 excellent. The mean score for each group was then calculated (Table 1).

Table (1): Aesthetic contour improvement in different types of abdominoplasty.

	Supra-umbilical contour	Infra-umbilical contour	Waist definition	Excess skin	Symmetry	Quality & Length of Scar	Aspect & Position of Navel
Classic abdominoplasty	Good	Excellent	Good	Poor	Excellent	Good	Good
Circumferential abdominoplasty	Good	Excellent	Poor	Good	Excellent	Poor	Good
Fluer-de-lis abdominoplasty	Excellent	Excellent	Excellent	Excellent	Excellent	Good	Good

Patient satisfaction was assessed by direct patient questioning and included subjective and objective feedback on overall satisfaction following abdominoplasty, areas of dissatisfaction and patient satisfaction following different types of abdominoplasty (Fig. 1).

The most common wound complication was seroma. It was encountered in 6 cases (20%), in these patients repeated percutaneous aspiration under sterile precautions was performed under broad spectrum antibiotic coverage and abdominal binder was worn continuously (day and night), this complication was successfully managed in all patients. Three patients (10%) had wound infections; they were treated by intra-venous antibiotics and wound drainage. Central skin necrosis was encountered in 1 case (3%); it was healed by secondary intention with repeated dressings in the outpatient clinic. One patient developed wound

dehiscence at the site of meeting of the horizontal and vertical incisions, where revision of the wound was done.

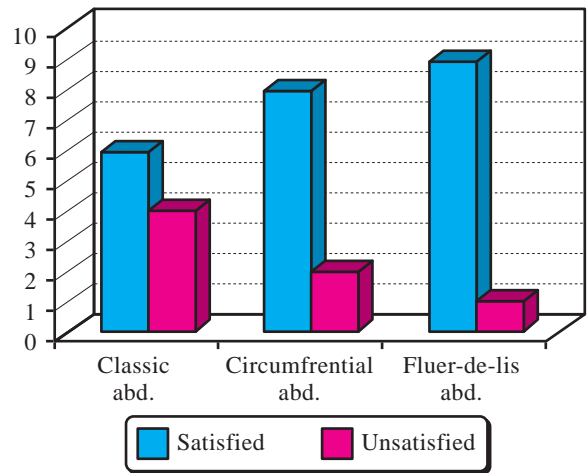


Fig. (1): Patient satisfaction with different types.

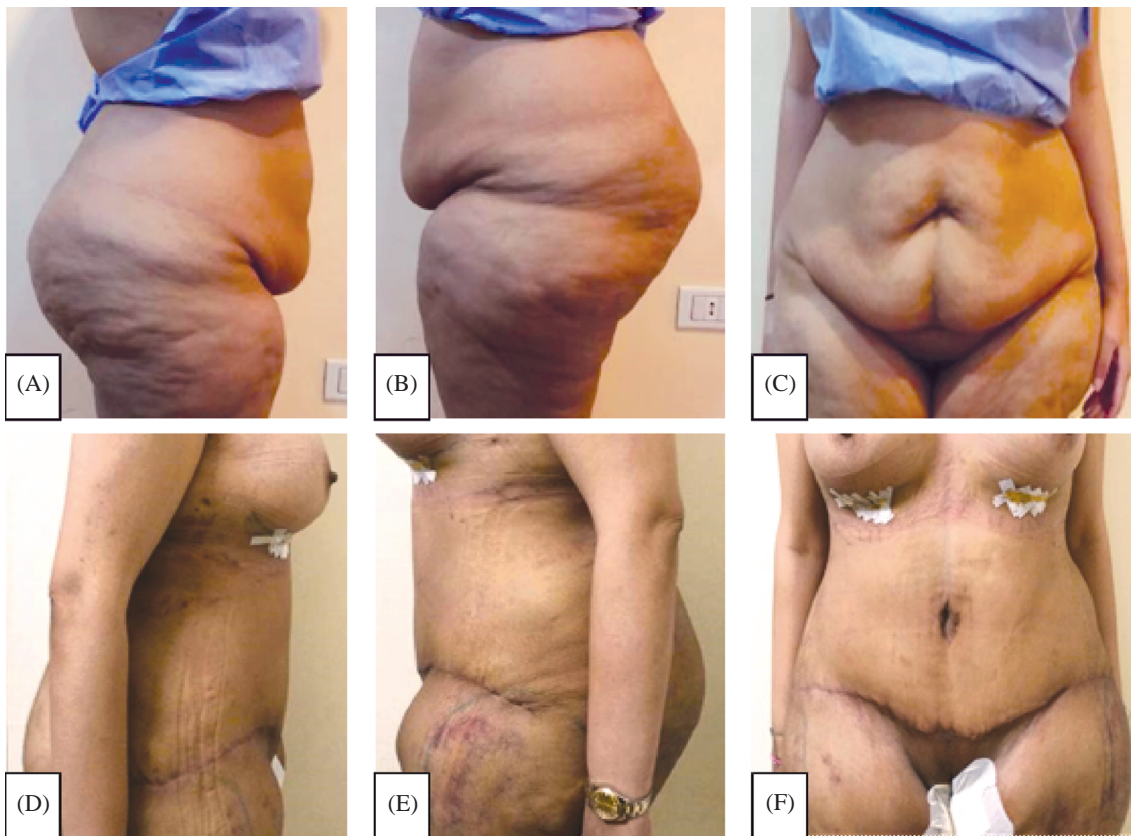


Fig. (2): Case Group A: Pre Operative (A, B, C) & Post Operative (D, E, F), frontal and lateral views. Patient underwent classic abdominoplasty and augmentation mastopexy.

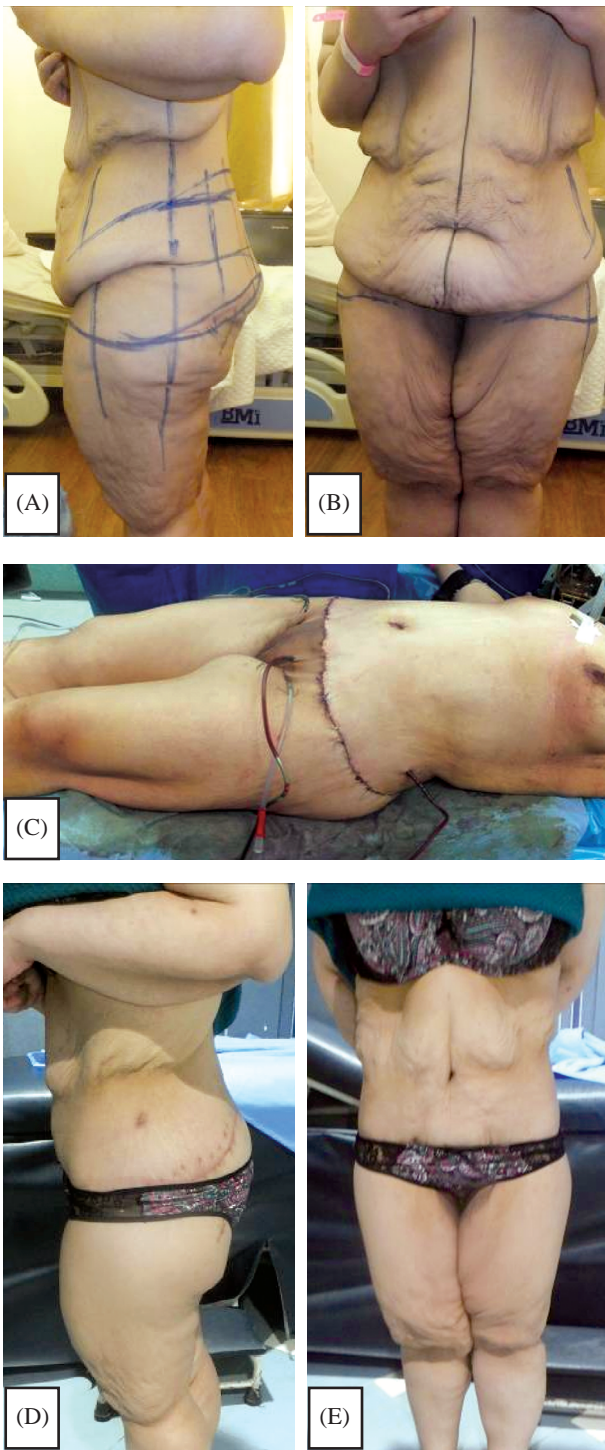


Fig. (3): Case Group B: Post bariatric 28 years old female, one year after laparoscopic sleeve gastrectomy Patient underwent circumferential (belt) abdominoplasty.

- A- Pre-Operative lateral view.
- B- Pre-Operative frontal view.
- C- Intra operative view after completion of circumferential abdominoplasty.
- D- Post-Operative lateral view.
- E- Post-Operative front view.

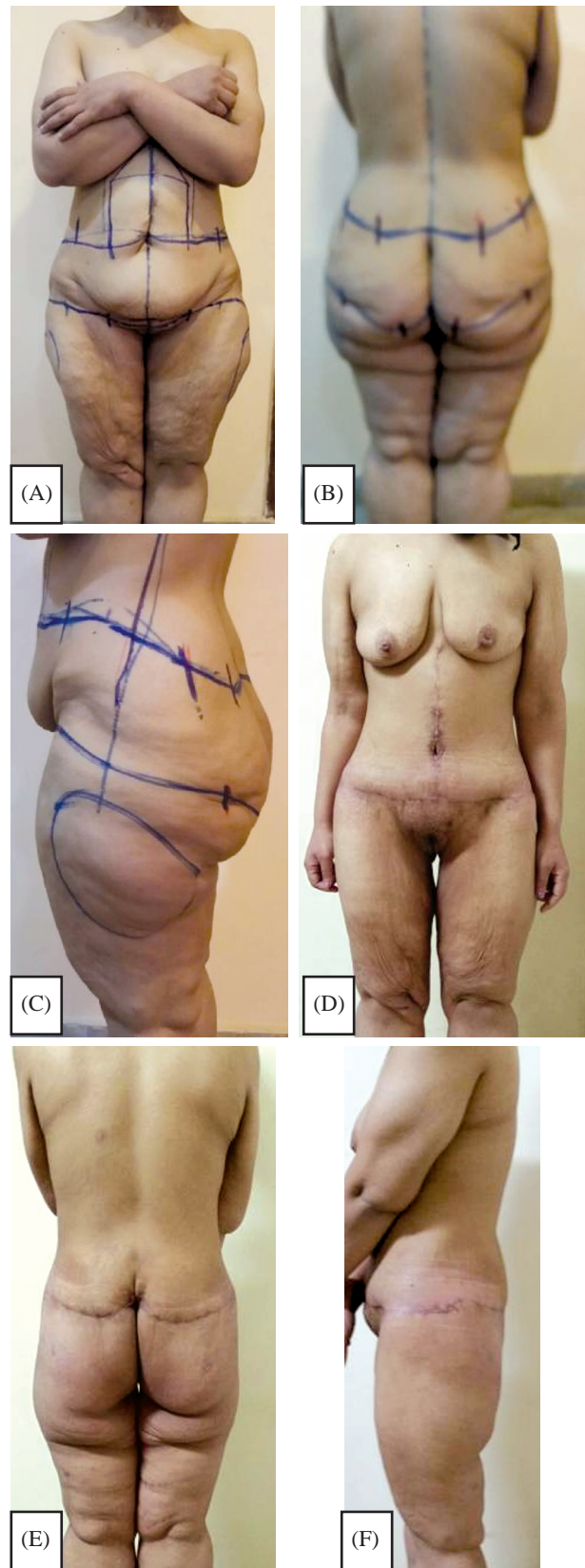


Fig. (4): Case Group C: A 32 years old female patient underwent circumferential fleur-de-lis (type T) abdominoplasty. A,B,C: Pre Operative showing frontal, back and left lateral views. D,E,F: Post Operative showing frontal, back and left lateral views (post 3 months).

## DISCUSSION

The definition of massive weight loss is the loss of weight greater than 100% above the person's ideal body weight [9,10]. Despite the fact that massive weight loss is mostly found in bariatric cases, a differentiation between patients who underwent a metabolic/bariatric procedure and those who lost weight via dieting and exercising is important; due to the nutritional deficiencies seen in patients undergoing these procedures. In addition, the difference between bariatric procedures is also important to understand and their basic working mechanism: As patients having purely restrictive procedures are less prone to have many of the metabolic complications as those who had malabsorptive procedure performed [11].

In obesity cases, bariatric surgery remains the ultimate solution when all other weight-loss methods have failed. However, cutaneous deformities resulting by massive weight loss are constant reminders to the patient of physical and psychological difficulties. Therefore, abdominoplasty is the most recommended treatment for abdominal skin laxity [9].

Commonly, a massive weight loss patient will seek a number of different procedures for the different anatomical regions. Therefore, the treatment plan can be affected by combining additional procedures to the abdominotorso contour surgery. Performing combined surgical procedures will increase the duration of the operation and its complexity, and may increase the risk of complications, need for blood transfusions, and requirement for extended hospital stays [12,13].

Abdominotorso contour surgery in the post bariatric weight loss patient entails a complex decision-making process to ensure the best result with the least amount of complications [14-18]. Therefore, a surgeon has to trade off in certain situations as regards the ideal choice of procedure versus complications. Prior surgical procedures can impact the choice of treatment, for example.

In 2006 Wallach developed an algorithm for treatment and classification of the abdominotorso region specifically for the massive weight loss. The described groups were assigned Types I through IV are those patients who have reached their weight goal. The type V patient (i.e., a panniculectomy) is the patient that has not achieved their ideal body weight and requires excision of the abdominal pannus to facilitate other surgical procedures.

In addition another classification of deformities of the contour after bariatric weight loss was Song described by Song et al. [19]. The system was based on the evaluation of 10 different anatomical regions commonly treated after massive weight loss (including the abdominotorso region). A table was used to illustrate preferred treatment plans for different anatomical regions based on this evaluation, but details regarding the various treatment plans were not clarified.

In the current study a more simple approach to post bariatric weight loss patients was used. Patients were classified in to three groups according to the distribution of skin laxity in the abdomen (both vertical and horizontal components where considered), buttocks and flanks. Patients were then regarded according to the abdominal laxities those with horizontal abdominal laxity only underwent conventional abdominoplasty (group A). Patients with a horizontal abdominal laxity and a laxity of the flanks and buttock areas underwent a circumferential abdominoplasty (group B). Those presenting with a vertical abdominal skin laxity underwent a fleur-de-lis abdominoplasty. In addition patients further suffering from buttock and flank redundancy a circumferential fleur-de-lis was performed (group C).

Analyzing the fat and skin excess of the abdominotorso region in both the vertical and horizontal planes is the key to a satisfactory outcome.

The traditional abdominoplasty does not fully address the significant functional and aesthetic changes to the torso following bariatric surgery: It does not properly consider the deformities of the redundant lateral flank and hip rolls. The lateral excesses may even be emphasized by the procedure increasing lateral fullness or leaving dog-ears. Moreover, ptosis is often present in the buttocks area as well. These issues are most frequently observed in patients with massive weight loss due to diet or some types of bariatric surgery procedure [10]. However with proper patient selection the classical abdominoplasty can achieve both good contour results and patient satisfaction with less operative time, lower morbidity and the least scar.

To improve the body contouring of the abdominotorso, the abdominoplasty should be extended circumferentially, without increasing operative and preoperative complications, in comparison to conventional abdominoplasty. Furthermore, the average hospital stay period does not change. The patients were very satisfied with the results of their procedures. We conclude that circumferential abdomi-

noplasty is an appropriate, effective and safe procedure to treat patients with abdominotorso lipodystrophy following massive weight loss [8].

Overall, fleur-de-lis abdominoplasty is a procedure that has been well established and tried over a long period and is frequently indicated to post-bariatric patients due to its low complication rate and good aesthetic results. It includes a vertical and low horizontal excision, leading to a better outcome in the abdominal girth and supra umbilical abdominal contour, and excising the redundant pannus. In addition, Mons pubis ptosis and flank and buttock contour deformities can be treated simultaneously. Even though fleur-de-lis with or without a circumferential component may improve the vertical laxity, this procedure improves the abdominotorso area further. Also the vast majority of patients who require an abdominoplasty and present with supraumbilical vertical midline or paramedian incisions, especially in case of concomitant abdominal procedures, a fleur-de-lis abdominoplasty should always be considered [20].

This was reinforced by the further Statistical analysis performed in this study; where the waist circumference measurements and vertical height measurements of each of the three groups showed a significant improvement in both waist circumference difference and a significant difference between the pre and post operative vertical length noted in as a significant difference between the pre and post operative xiphi-sternum to umbilical distance and not the umbilical to the symphysis distance. Yet stressing that with proper preoperative evaluation patients can individually benefit from a selected procedure suited for the presenting case.

However overall comparison between the 3 groups also proved to be significantly different. The waist circumference difference statistically was significant ( $p$ -value  $<0.05$ ); the mean value being  $-6.8$  in group A (patients undergoing a classical abdominoplasty),  $-11.40$  in group B (a belt lipectomy procedure) and  $-17.60$  in group C (fleur de lis combined with or without a circumferential horizontal component). Fleur-de-lis showing the most optimal outcome as regards aesthetic contour measurements; this can be contributed to the fact that it is the only of the three procedures that addresses the vertical redundancy thereby including all vectors in the abdominotorso reshaping procedure. This procedure should always be considered in post bariatric weight loss patients as most of those present with a midline or paramedian scar thus not adding to the scar morbidity of the abdominotorso contour procedure.

In this study, all of the patients were females. This is inline with the work of Sozer et al. [21] whose whole group of 151 patients were female. However, this differs from other comparative works [8,11] which had female to male incidence of 2:1. This may be attributed to the socioeconomic class of Kasr Al Aini patients who were the subject of this study. The mean age of the studied groups of patients in this work was 36 years; a bit younger than that of Aly et al., 2003 and Dini et al. 2008 (43.6 years) and 42 years for Sozer et al. [21]. Again this difference may be attributed to the fact that in low socioeconomic classes the elderly patients are not concerned with the problem of attractiveness.

The incidence of associated ventral hernias was the same other studies (20%) [8,21]. An umbilical or incisional hernia usually does not affect the choice of surgical operation but may affect the complexity and length of the surgery, adding to the overall risk [37-41]. The viability of the umbilicus may be also affected and must be therefore considered in the preoperative plan, and when a ventral hernia is repaired, it may impede the quality of the diastasis repair.

Wound complication rate (36%) was almost similar to results of the recent studies on the incidence of post abdominoplasty wound complication rates of 11-32% as referred to Sozer et al. [21], this high complication result could be attributed mainly to the metabolic and nutritional side effects coupled with bariatric procedures, being a significant risk factor for increasing wound complications rate following abdominoplasty.

Seroma was found to be the most common complication in our study. It occurred in 6 patients (20%). Khan, 2008 studied the incidence of seroma following abdominoplasty and was found to be variable and ranged from 1-26%. This incidence was correlated to systemic factors in the patients as bleeding tendency, drug intake (aspirin), diabetes, increased BMI, and the plane of flap dissection; the more superficial the plane as in sub and supra-scarpal dissection, the less the incidence of seroma, the same results was mentioned [10].

#### *Conclusion:*

The contour of the abdomen is the backbone of body contouring surgery. Post bariatric patients usually seek abdominoplasty to correct excess skin, abdominal wall laxity, striae, or diastasis of the rectus muscles.

As a whole most of the patients in this study were uniformly pleased with their results. They were pleased with their new image.

All three procedures in this study for abdominal contouring obtain both, good functional and, in most cases acceptable aesthetic results. However statistically there was a significant inclination towards the fleur-de-lis approach followed by a belt lipectomy, followed by the classical abdominoplasty. This was also demonstrated in the patient satisfaction and overall surgeon evaluation. In General, post-bariatric procedures exhibit a significant effect on the patients' quality of life, especially in relation to their "self-image" and their "self-esteem".

The proper choice of the technique of abdominoplasty for post bariatric patient depends on the distribution of excess laxity, whether circumferential laxity where circumferential abdominoplasty is done or ventral laxity where classic or Fleur-de-lis abdominoplasty is done.

### REFERENCES

- 1- Espinosa-de-los-Monteros A., Jorge I.T., Laurence Z.R., et al.: Abdominoplasty with total abdominal liposuction for patients with massive weight loss. *Aesthetic Plastic Surgery*, 30 (1): 42-46, 2006.
- 2- Strauch B., Herman C., Rohde C., et al.: Mid-body contouring in the post-bariatric surgery patient. *Plast. Reconstr. Surg.*, 117: 2200-2211, 2006.
- 3- Bozola A.R. and Psillakis J.M.: Abdominoplasty: A new concept and classification for treatment. *Plastic Reconstr. Surg.*, 82 (6): 983-93, 1988.
- 4- Glonzalez-Ulloa M.: Belt Lipectomy. *Br. J. Plastic Surg.*, 13: 179, 1961.
- 5- Muhlbauer W.: Radical Abdominoplasty, Including Body Shaping: Representative Cases. *Aesth. Plast. Surg.*, 13: 1-5-110 1989.
- 6- Castanares S. and Goethel J.A.: Abdominal Lipectomy: A modification in technique. *Plast. Reconstr. Surg.*, 40: 378-383, 1967.
- 7- Pitanguy I., Mayer B. and Labrakis G.: Abdominoplasty: Personal surgical guidelines. *Zentralbl Chir.*, 113: 765-71, 1988.
- 8- Dini M., Mori A., Lorenzo Calì Cassi, et al.: Circumferential Abdominoplasty. *Obes. Surg.*, 18: 1392-1399, 2008.
- 9- Hester T.R. Jr., Baird W., Bostwick J., et al.: Abdominoplasty combined with other major surgical procedures: Safe or sorry? *Plast. Reconstr. Surg.*, 83: 997-1004, 1989.
- 10- Khan U.D.: Risk of seroma with simultaneous liposuction and abdominoplasty and the role of progressive tension sutures: *Aesthetic Plast. Surg.*, 32 (1): 93e9, 2008.
- 11- Aly A.S., Cram A.E., Chao M., et al.: Belt lipectomy for circumferential truncal excess: The University of Iowa experience. *Plast. Reconstr. Surg.*, 111 (1): 398-413, 2003.
- 12- Hunter G.R., Carpo R.O., Broadbent T.R., et al.: Pulmonary Complications Following Abdominal Lipectomy. *Plast. Reconstr. Surg.*, 71: 809, 1983.
- 13- Voss S.C., Sharp H.C. and Scott J.R.: Abdominoplasty Combined with gynecologic surgical procedures. *Obstet. Gynecol.*, 67: 181, 1986.
- 14- Duff C.G., Aslam S. and Griffiths R.W.: Fleur-de-lys abdominoplasty: A consecutive case series. *Br. J. Plast. Surg.*, 56: 557, 2003.
- 15- Wallach S.G.: Abdominal contour surgery for the massive weight loss patient: The fleur-de-lis approach. *Aesthetic Surg. J.*, 25: 454, 2005.
- 16- Strauch B., Herman C., Rohde C. and Baum T.: Mid-body Contouring In The Post-bariatric surgery patient. *Plast. Reconstr. Surg.*, 117: 2200, 2006.
- 17- Matry W.E. Jr., O'Sullivan J., Fudem G. and Dunn R.: Abdominal surgery in patients with severe morbid obesity. *Plast. Reconstr. Surg.*, 94: 976, 1994.
- 18- Vastine V.L., Morgan R.F., Gampper T.J., et al.: Wound Complications of Abdominoplasty in Obese Patients. *Ann. Plast. Surg.*, 42: 34, 1999.
- 19- Song A., Jean R. and Hurwitz D.: A classification of contour deformities after bariatric weight loss: The Pittsburgh rating scale. *plast. Reconstr. Surg.*, 116 (5): 1535-1544, 2006.
- 20- Persichetti P., Simone P., Cogliandro A. and Scuderi N.: *Body Contouring*, Springer-Verlag Berlin Heidelberg, 10-1007, 2010.
- 21- Sozer S.O. and Agullo F.J.: Triple plication in miniabdominoplasty. *Aesth. Plast. Surg.*, 30: 263-268, 2007.